Frequent non-sustained VT and Presyncope

Where is the origin?



ARYA EP TALKS

Introduction

- 56-year-old male patient
- Known case of CAD (2VD), CABG.
- LVEF: 45%
- Admitted to our ER due to frequent palpitation and presyncope.
- What is the diagnosis?

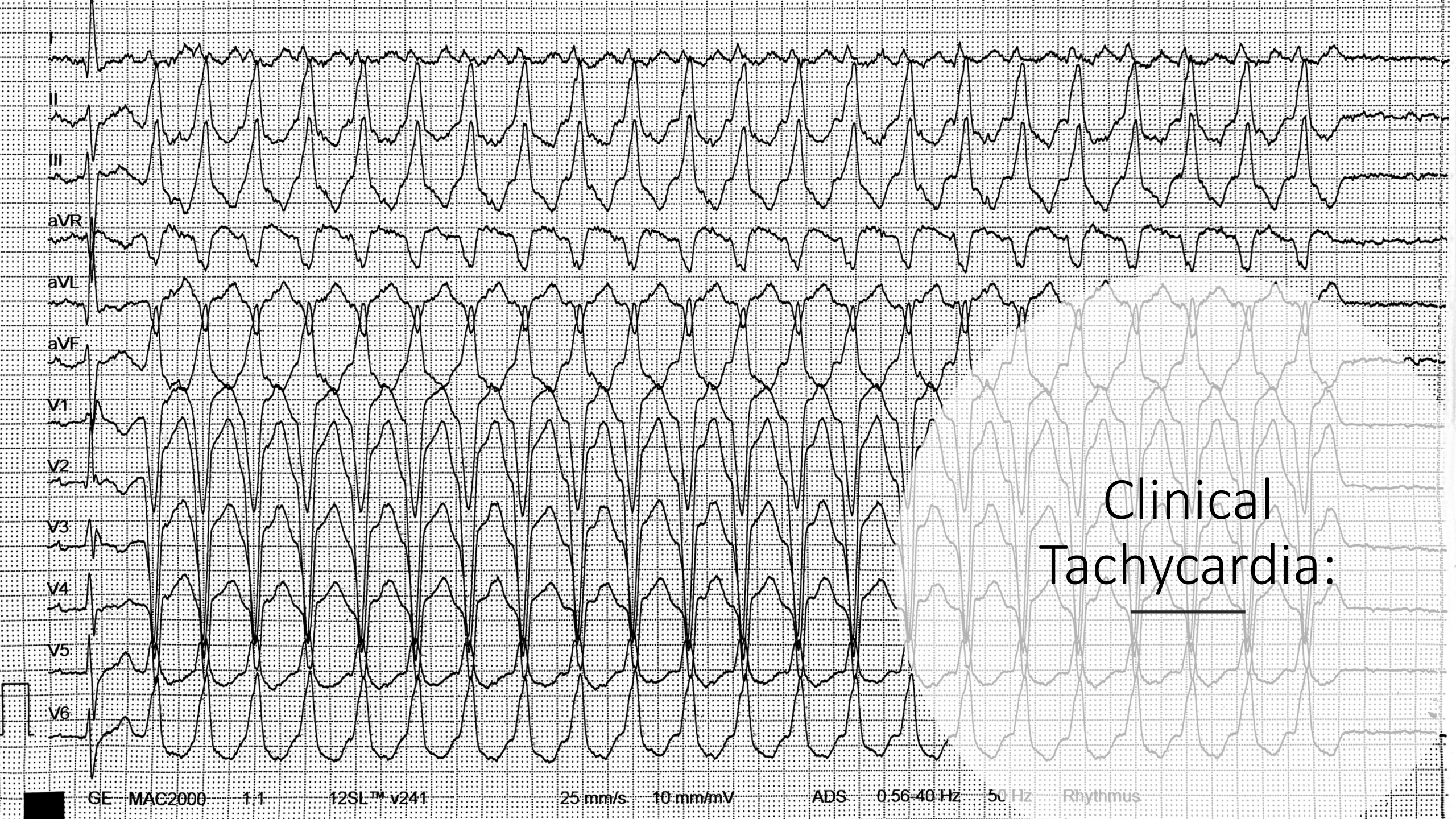

Clinical Tachycardia:

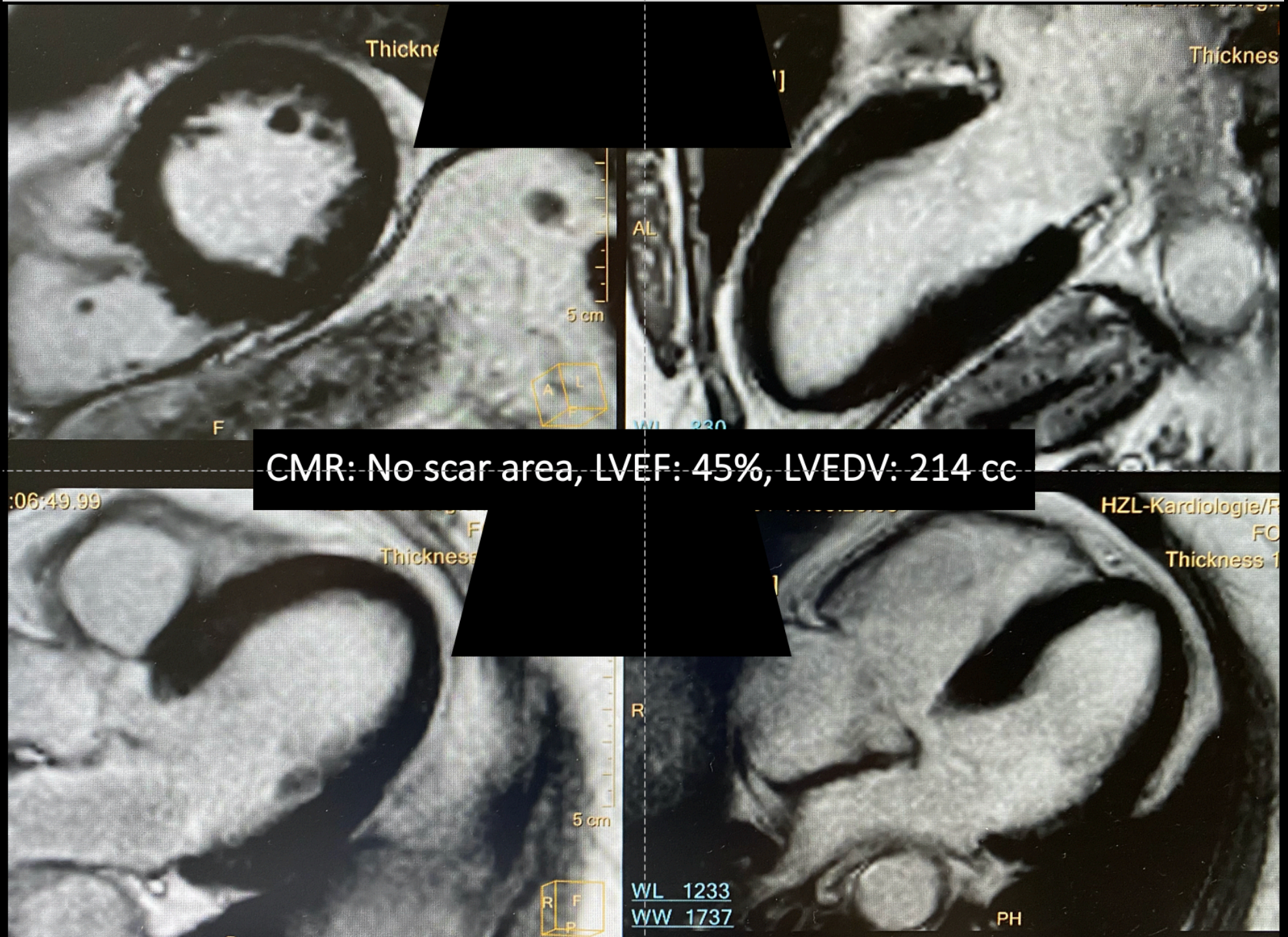

CMR: No scar area, LVEF: 45%, LVEDV: 214 cc

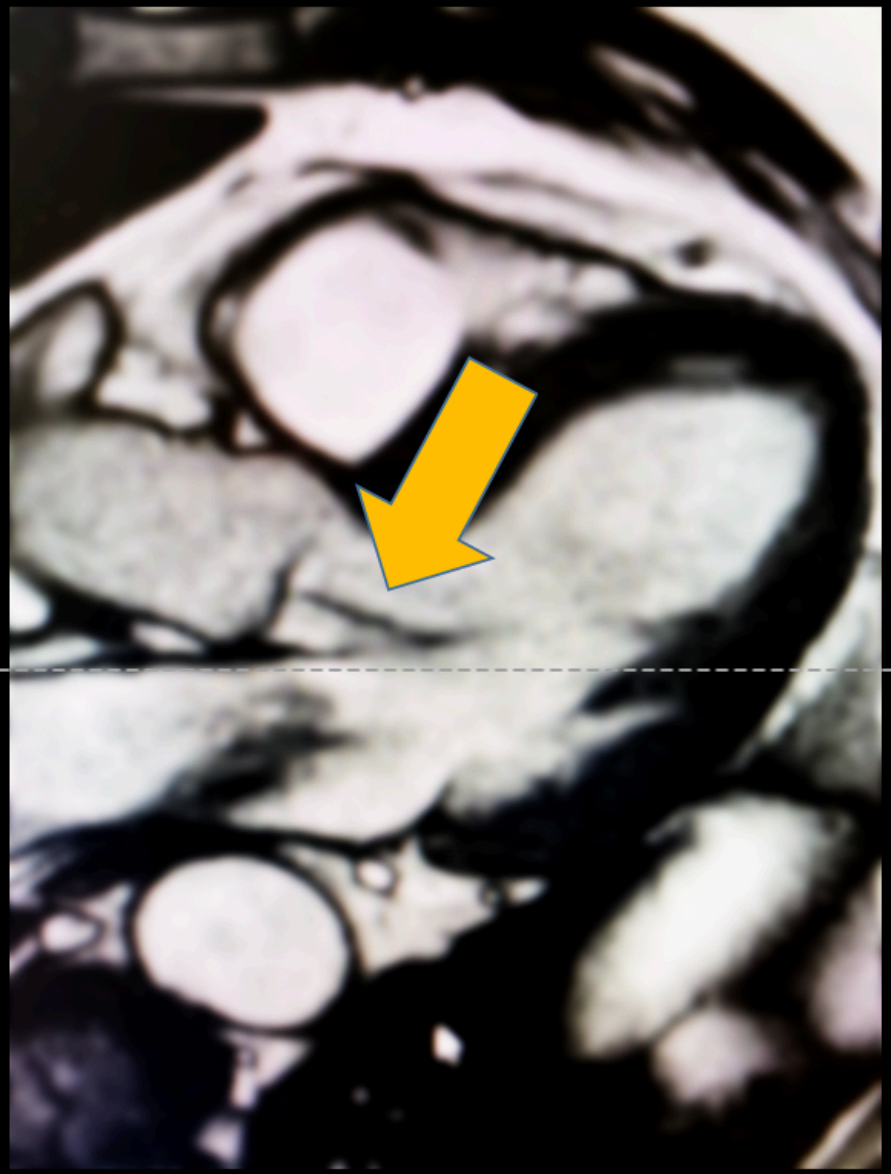

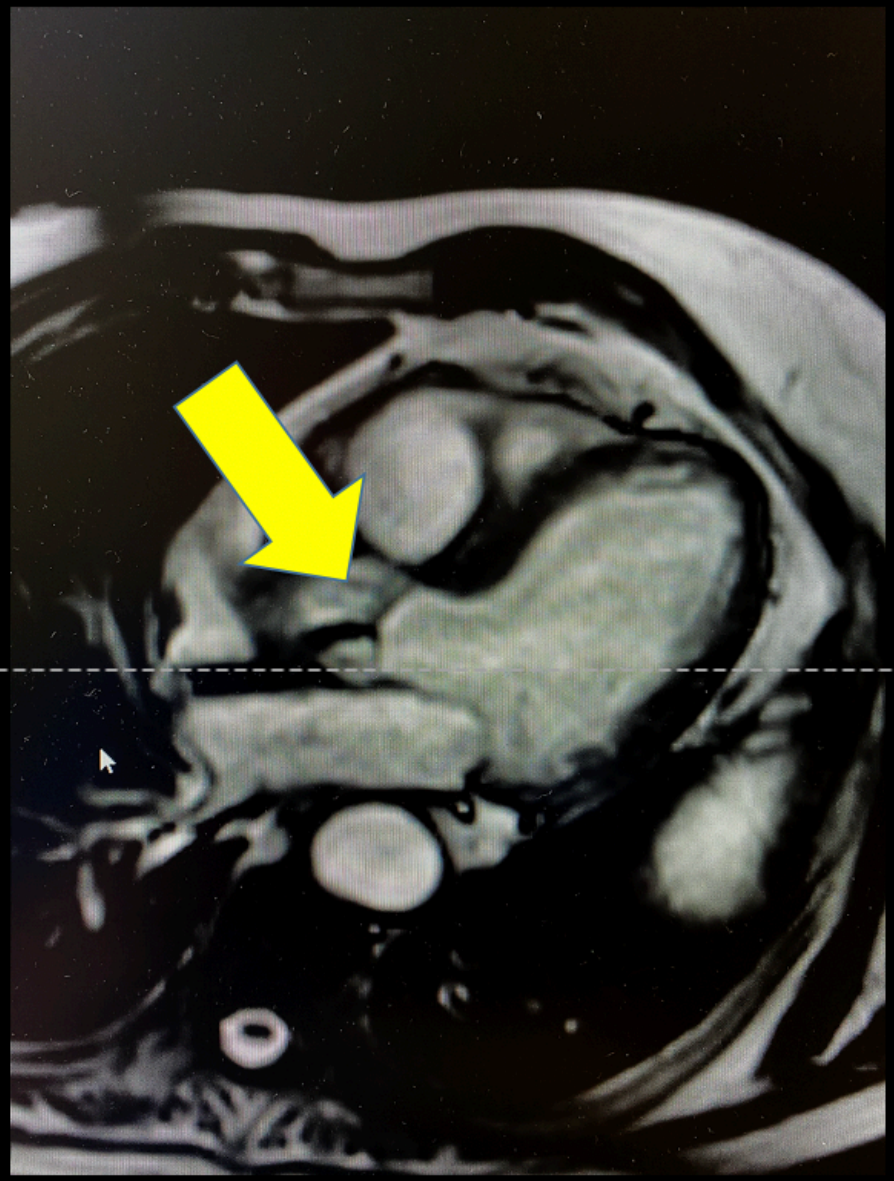

Looking Beyond Tachycardia: moderate AS and mild AI

Diagnosis:

- Idiopathic VT from RVOT *(not scar related)*
- Moderate AS (presyncope)
- Successful ablation of idiopathic VT
- No need for ICD Implantation