ECG EXERCISES

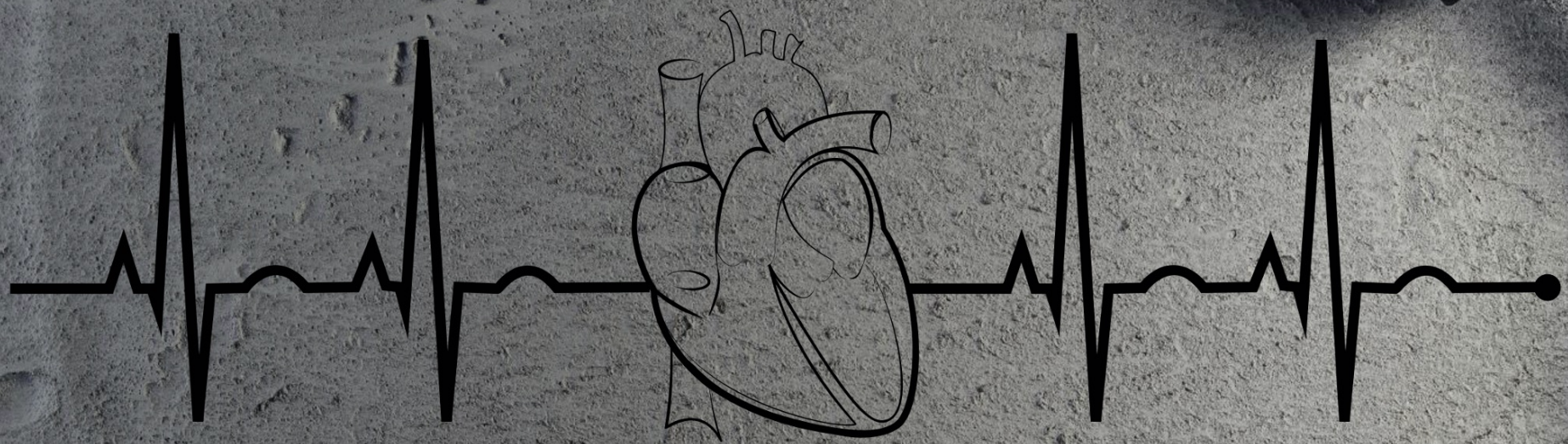

08.06.2020: Supraventricular Tachycardia

Courtesy of Dr. Angeliki Darma

ECG: 25 mm/s, 50-year-old female patient with frequent palpitations, CL: 440 ms

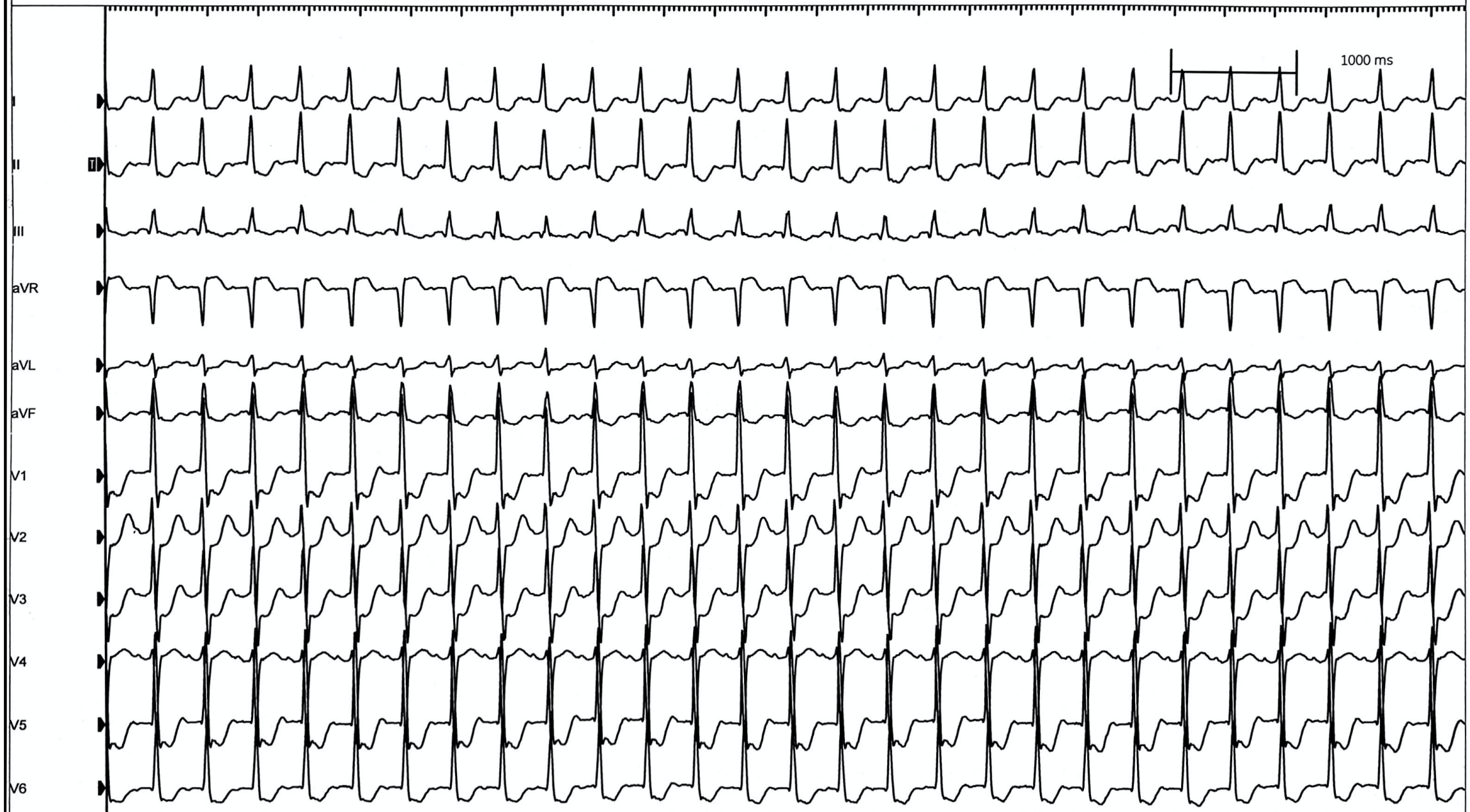

Questions:

(1) What is the mechanism of the tachycardia?
(2) Where is the origin of the tachycardia?

The answer as a video presentation will be uploaded on 11.06.2020

This Presentation and its contents are copyright of Arash Arya
© Arash Arya 2020. All rights reserved.

Any redistribution or reproduction of part or all the contents in any form is prohibited other than the following:
(1) you may print or download to a local hard disk extracts for your personal and non-commercial use only
(2) you may copy the content to individual third parties for their personal use, but only if you acknowledge the website as the source of the material

You may not, except with our express written permission, distribute or commercially exploit the content. Nor may you transmit it or store it in any other website or other form of electronic retrieval system.