

Catheter Ablation of Ischemic VT

ECG Exercises for VT Exit Localization

Part 2: Old Anterior Myocardial Infarction

This page and its content is copyright of Arash Arya -
© Arash Arya 2019. All rights reserved.

Any redistribution or reproduction of part or all of the contents in any form is prohibited other than the following:

- you may print or download to a local hard disk extracts for your personal and non-commercial use only
- you may copy the content to individual third parties for their personal use, but only if you acknowledge the website as the source of the material

You may not, except with our express written permission, distribute or commercially exploit the content. Nor may you transmit it or store it in any other website or other form of electronic retrieval system.

Clinical History:

- 75 Years Old Male Patient
- Old Anterior Wall MI, LVEF: 30%
- Electrical Storm due to Recurrent Frequent Therapy Refractory VTs leading to ICD Therapies
- Patient Referred for Catheter Ablation

Baseline ECG

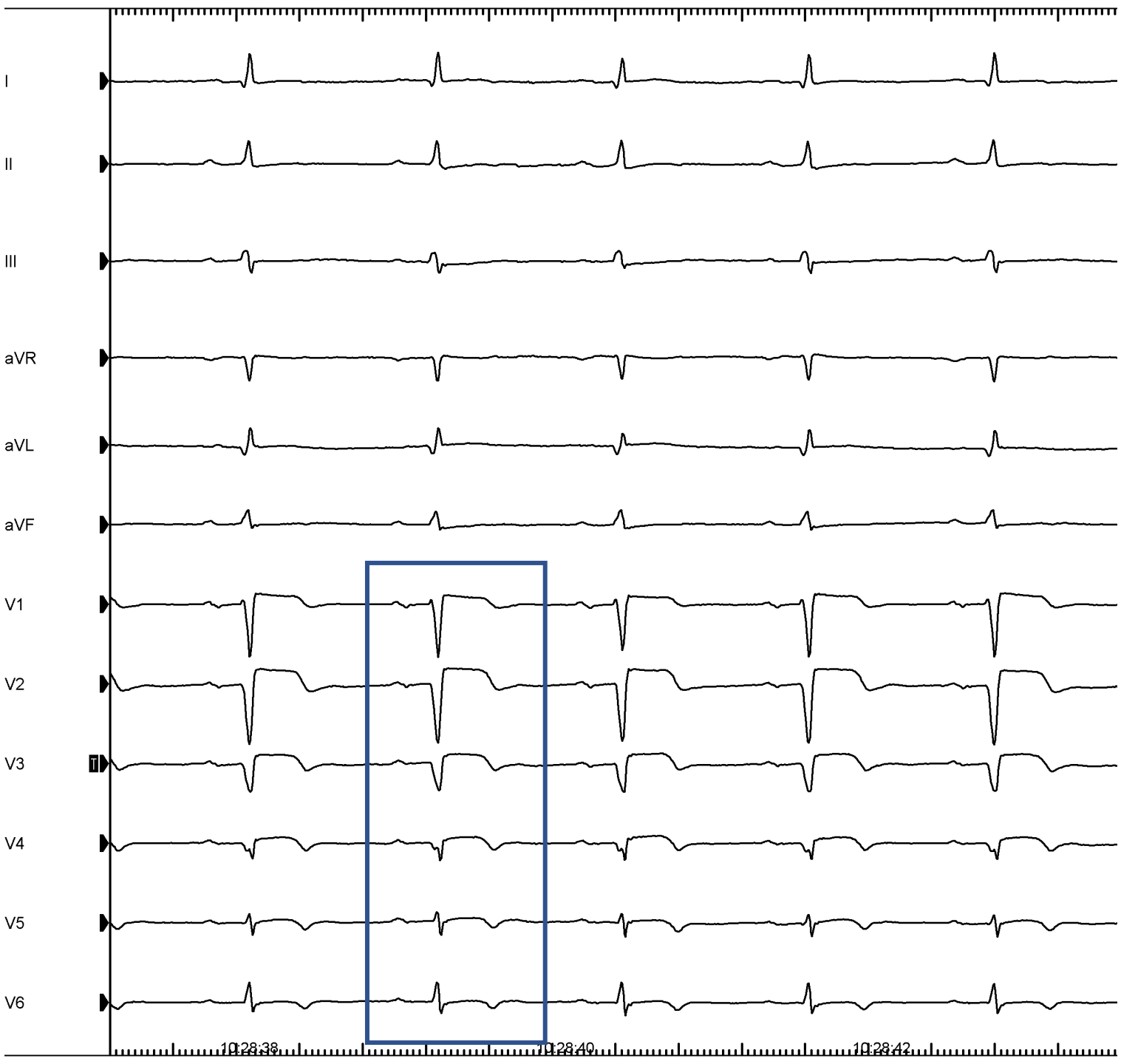

VT1

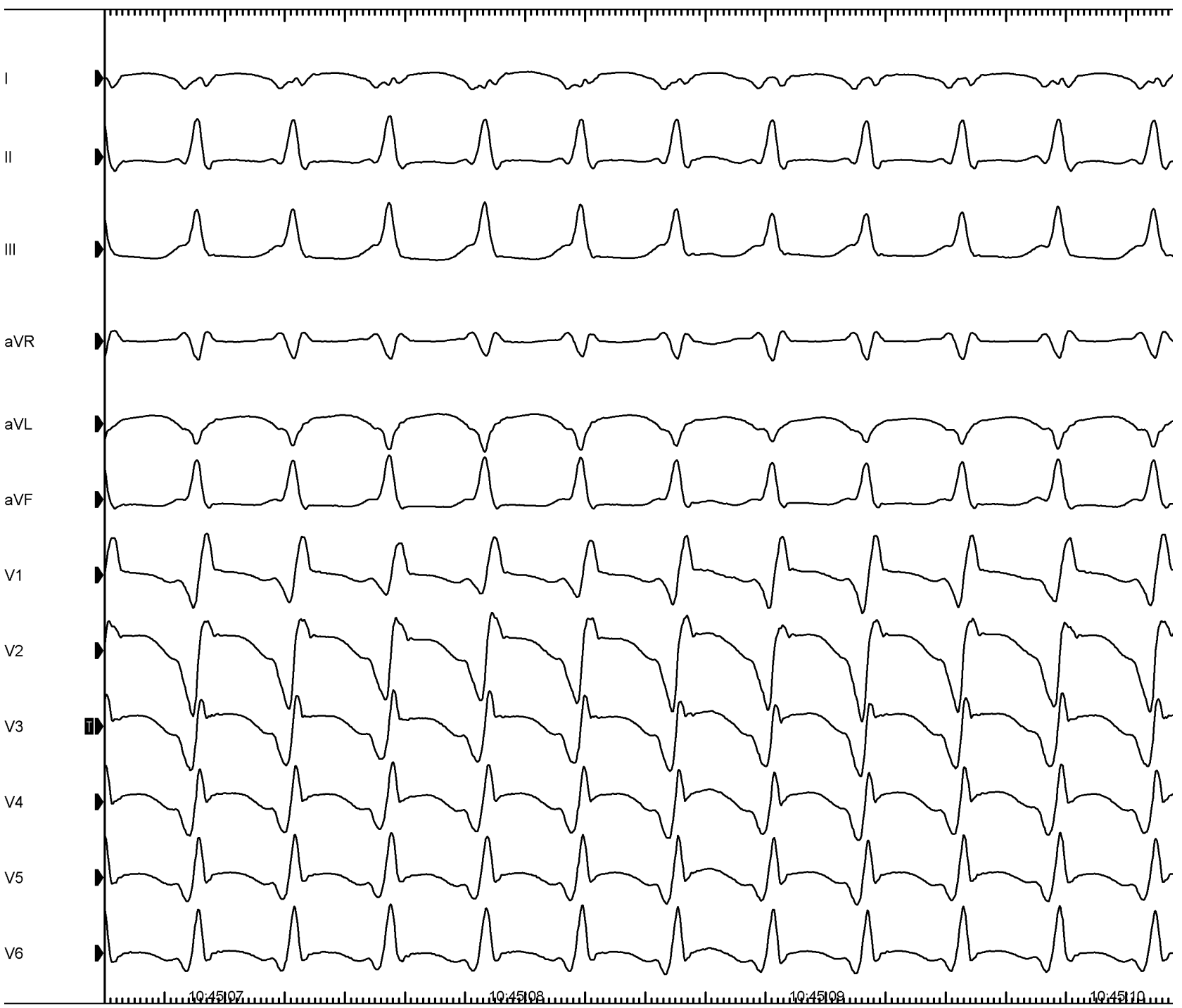
I
II
III
aVR
aVL
aVF
V1
V2
V3
V4
V5
V6
10:45:07
10:45:08
10:45:09
10:45:10

VT2

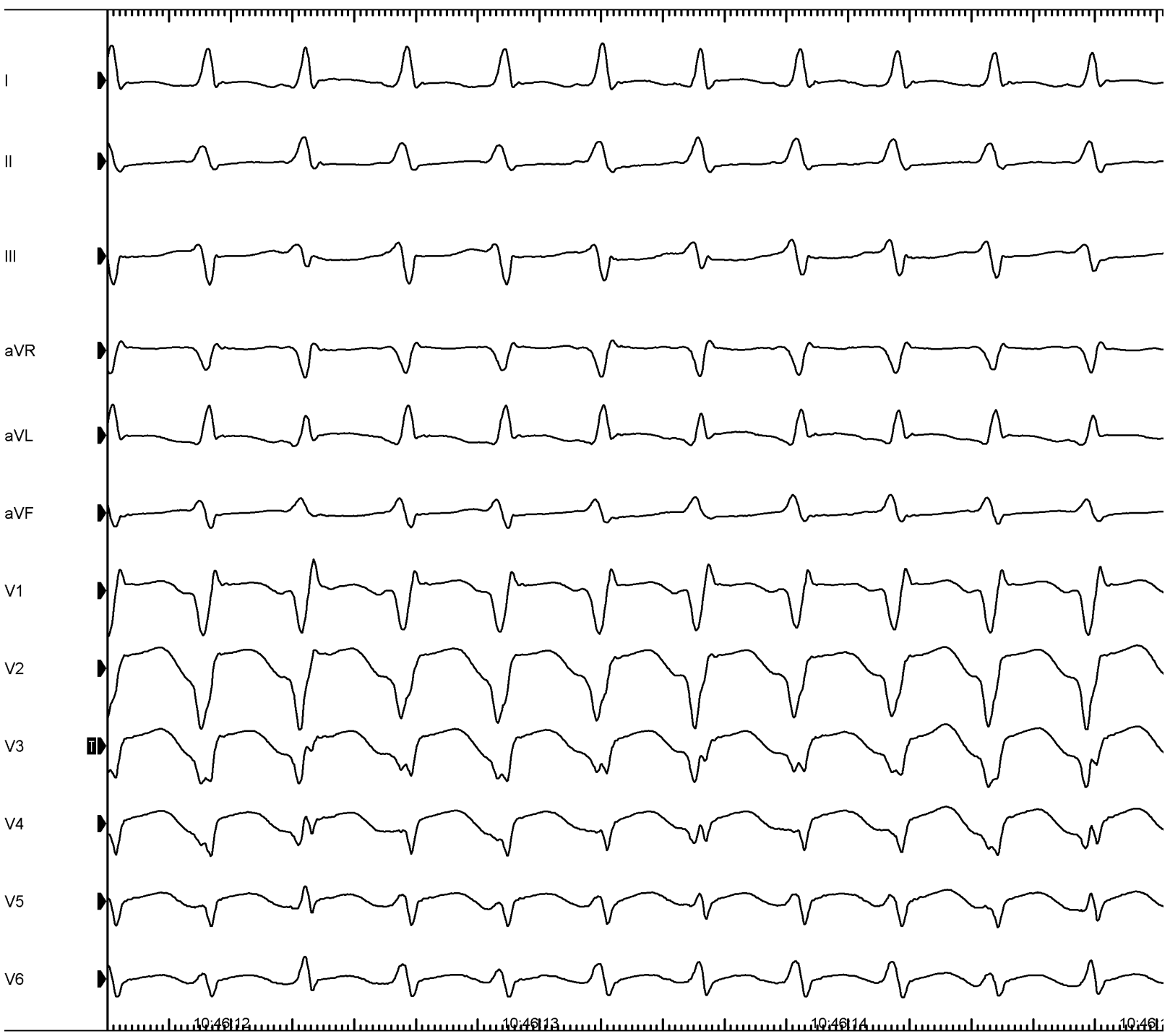

VT3

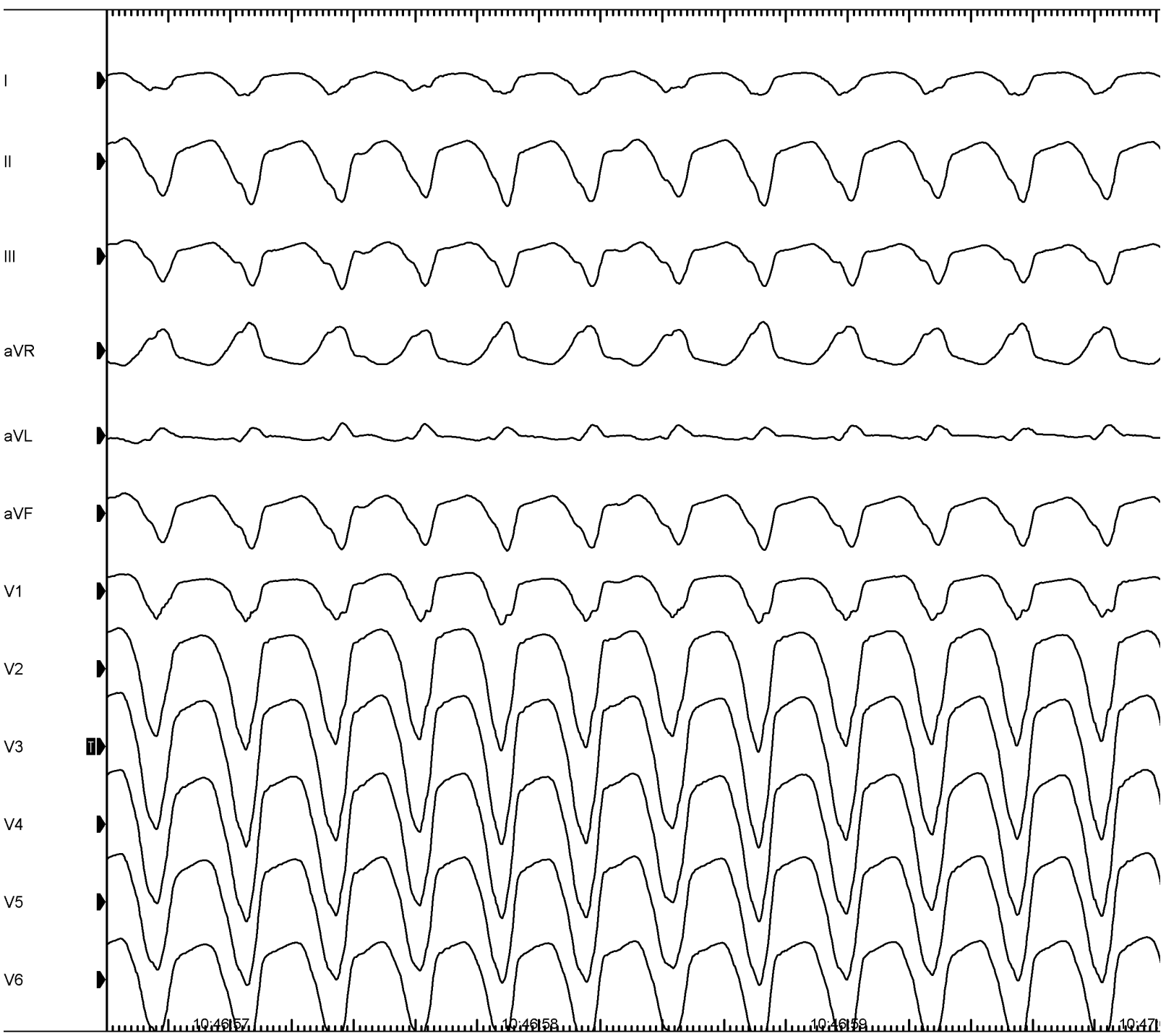

VT4

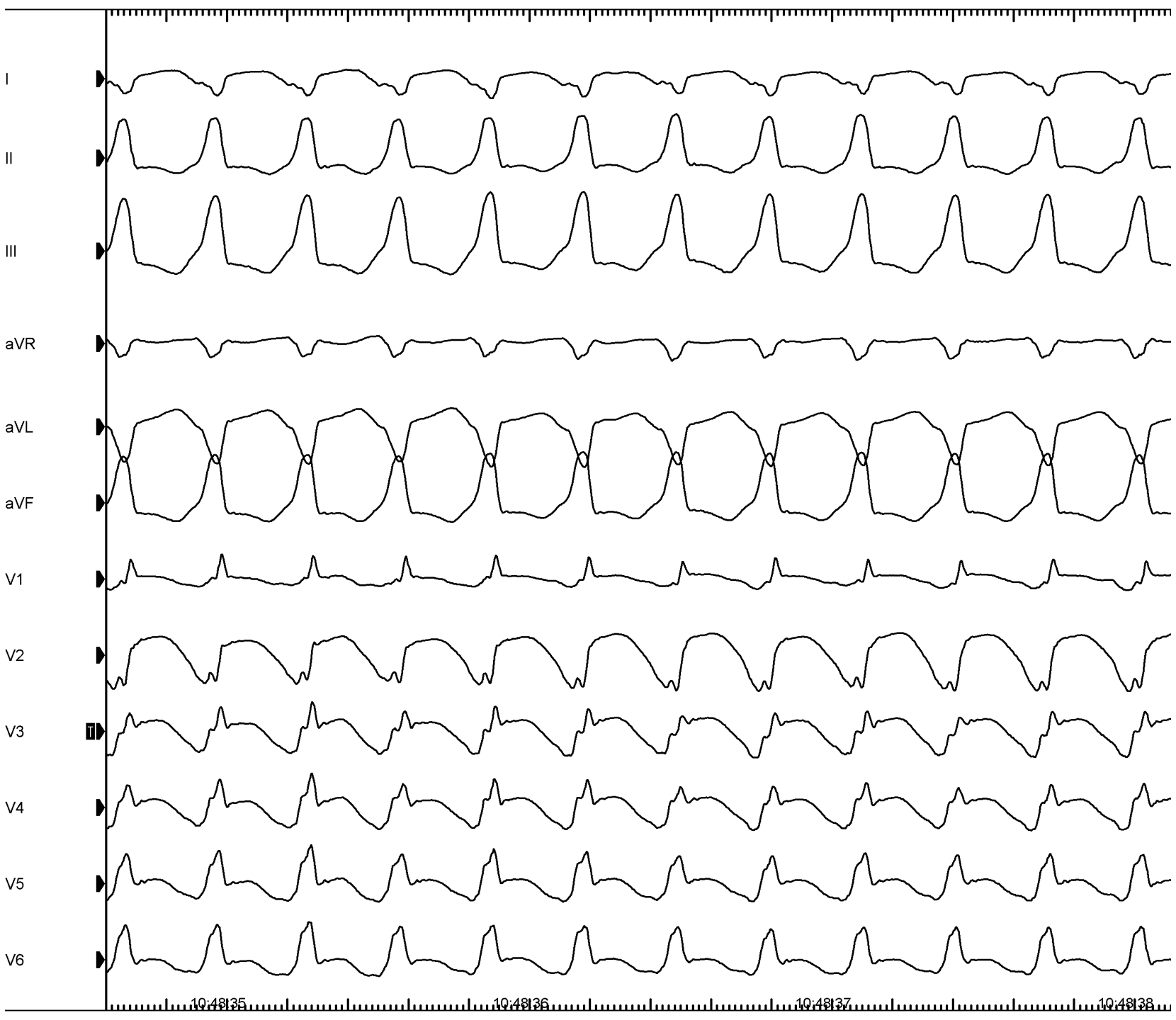
I
II
III
aVR
aVL
aVF
V1
V2
V3
V4
V5
V6
10:48:35
10:48:36
10:48:37
10:48:38

VT5

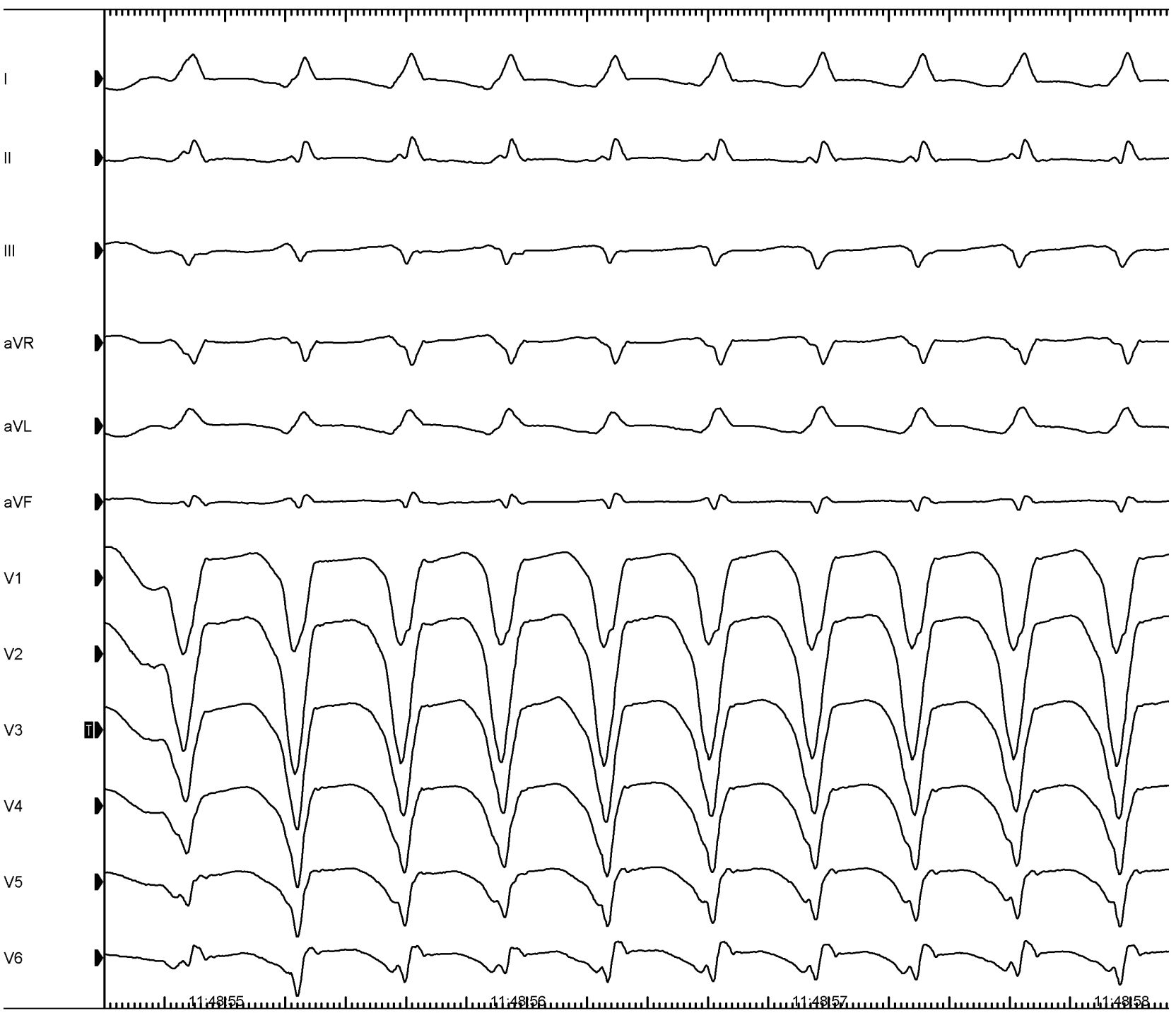
I
II
III
aVR
aVL
aVF
V1
V2
V3
V4
V5
V6
11:48:55
11:48:56
11:48:57
11:48:58

VT6/7

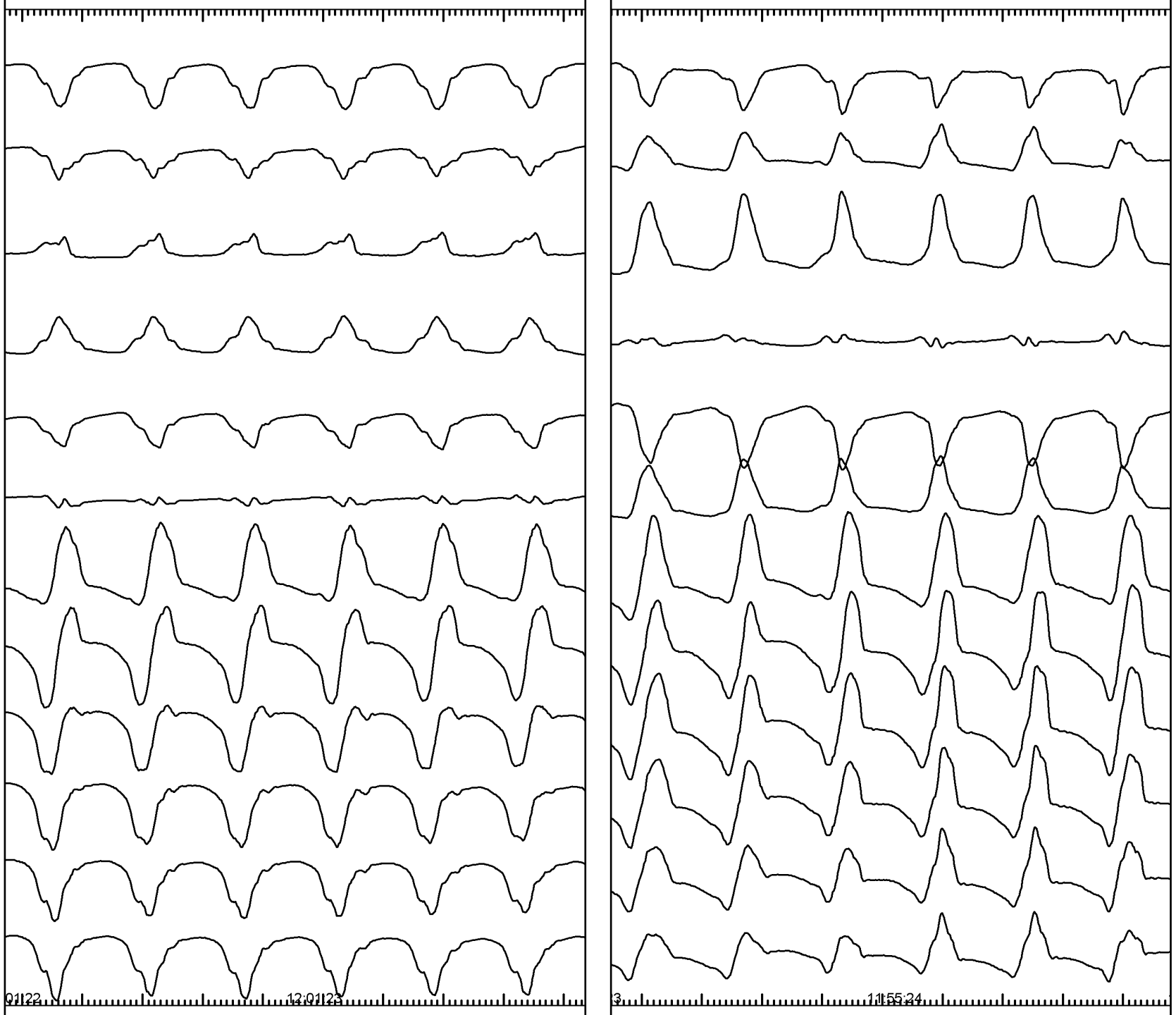

Electro-anatomical Mapping

Match the VT Morphologies with Exits

Solution in the next Slide

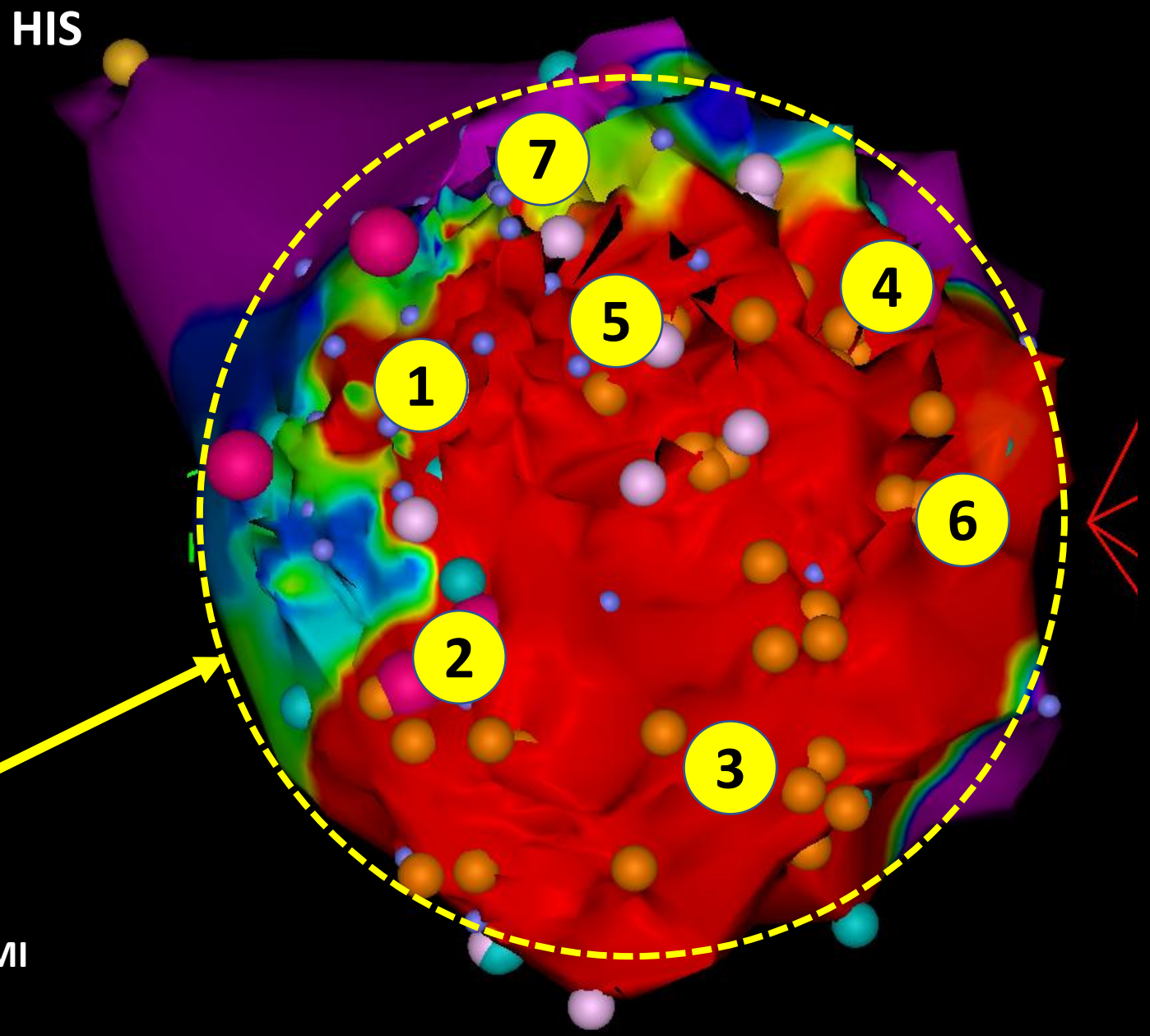

Large Apical Aneurysm after Anterior MI

LAO View, Orange points show LPs

Electro-anatomical Mapping

1 VT2
3 VT3
5 VT4
2 VT5
4 VT7
6 VT6
7 VT1

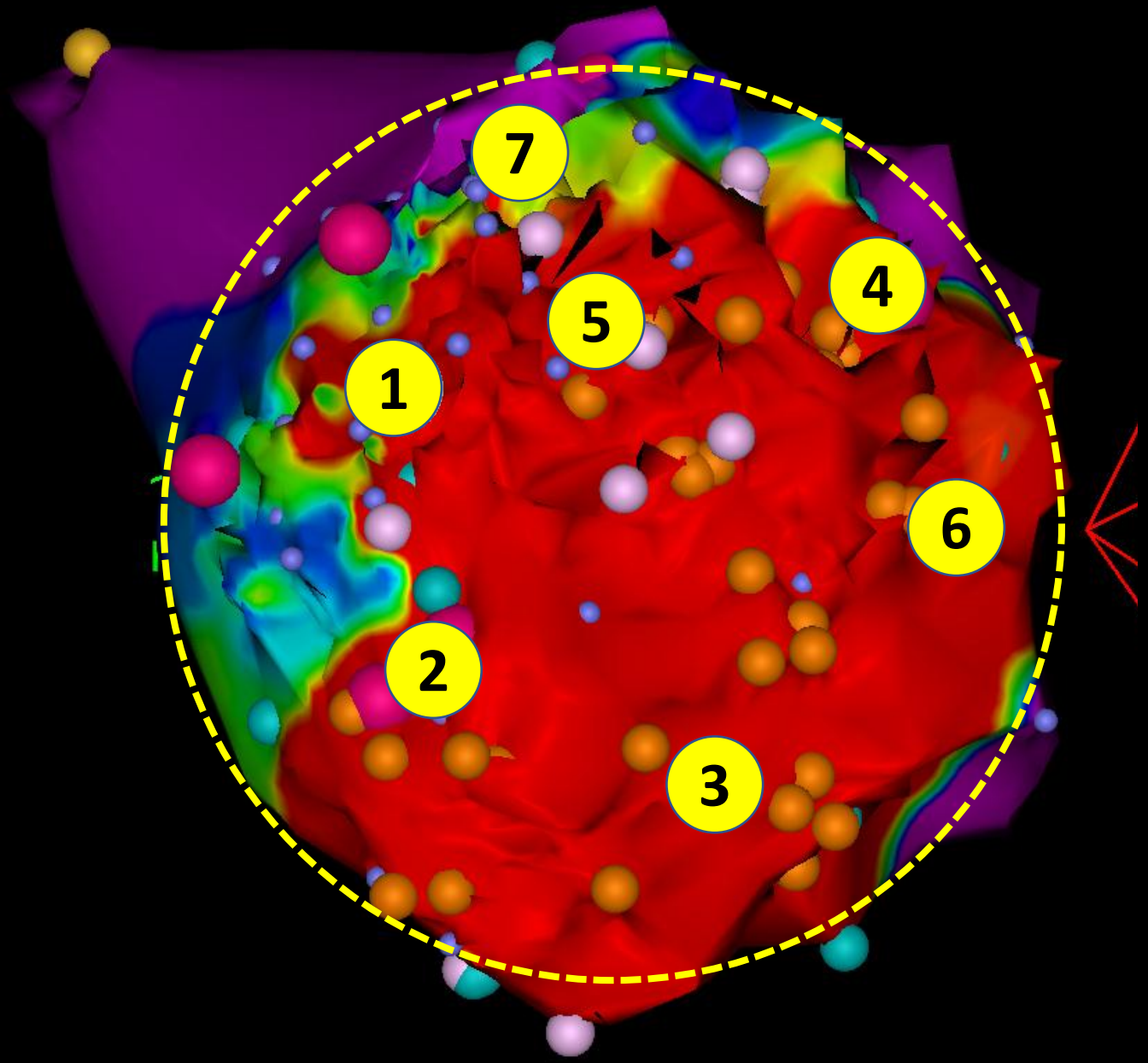

LAO View, Orange points show LPs

Hospital Course:

- Successful Ablation of *all* VTs
- Ablation of *all* LPs
- Uneventful hospital stay
- No further VTs

See Also: https://www.arasharya.de/app/download/9922438/EKG+Übungen.pdf